

Dx Imaging Midterm Compilation

Midterm A

- 1.) Select the source of increased signal intensity within the spinal canal on a T-2 weighted MRI image.
    - a. Nerve root
    - b. Spinal cord
    - c. **Cerebrospinal fluid - white on T-2 because high composition of water**
    - d. PLL
  - 2.) Which complication is likely if a patient with a grade III hyperflexion cervical sprain underwent a high velocity spinal manipulation?
    - a. Spinal cord compression
    - b. Retropharyngeal hematoma
    - c. **Discogenic spondylosis**
    - d. Diffuse intervertebral ossification
- Classifications of Hyperflexion Injury
- Grade 1 - entirely clinical pain in neck with interspinous tenderness
  - Grade 2 - torn ligaments enough to gap the interspinous space
  - Grade 3 - hyperflexion sprain, traumatic intersegmental **instability**, gapping of spinous, dislocation of the facets, segmental instability
  - Grade 4 - U/L or B/L dislocation
- 3.) Identify the diagnosis responsible for recurrent and progressive shoulder dislocation.
    - a. **Syrinx**
    - b. Biceps tendonitis
    - c. Triceps tendonitis
    - d. Rotator cuff tear
  - 4.) What is the mechanism of injury that produces a Grade III cervical sprain?
    - a. **Flexion**
    - b. Shear
    - c. Rotation
    - d. Extension
  - 5.) A patient sustained a cervical spine injury and developed an upper motor neuron lesion. What findings were present?
    - a. **Babinski positive**
    - b. Hyporeflexia
    - c. Clonus
    - d. Hyperflexia
  - 6.) Select diagnosis most likely to result in cord compression.
    - a. Spinous process fracture
    - b. **Diffuse idiopathic skeletal hyperostosis** *DISH > calcification of PLL will cause cord compression*
    - c. Schmorl's Herniation
    - d. Nuchal ligament tear

- 7.) Weakness of the flexor carpi ulnaris is likely to arise from which level of foraminal encroachment?
- C4
  - C5
  - C6
  - C7**
- 
- 7.) What is the etiology of degenerative anterolisthesis?
- Uncovertebral arthrosis
  - Spondylolysis
  - Apophyseal arthrosis**
  - Herniation of nucleus pulposus
- 8.) Which diagnosis is associated with a atlantoaxial instability?
- Short neural arch C1
  - Spondylolisthesis (pars defect)
  - Transverse ligament tear**
  - Os odontoideum
- 9.) Select the differential diagnosis of an increased retropharyngeal space. (multiple)
- Nuchal ligament tear
  - Acute hematoma**
  - Abscess**
  - Anterior disc herniation
- 10.) The presence of the cauda equina syndrome is suggested by what signs? (multiple)
- Babinski positive
  - Leg weakness**
  - ~~Hyperreflexia~~
  - Saddle distribution paresthesia**
  - incontinence**
- 
- 11.) A lateral lumbar radiograph reveals disc space thinning with a horizontal lucency. The endplates are sclerotic with irregularity. Consider which radiologic diagnosis?
- Spondylosis deformans
  - Osteoarthritis**
  - Intervertebral osteochondrosis
  - DISH
- 12.) The somatosensory evoked potential (SSEP) exam evaluates which property of axons?
- Axoplasmic velocity
  - Latency period**
  - Adventitial period
  - Reperfusion period
- 13.) The "fingerprints" of a cervical extension injury seen on a lateral radiograph. (multiple)
- Anterior disc space widening**
  - Pillar fracture**
  - Segmental kyphosis - flexion
-

- d. Interspinous gap – flexion
- 14.) The AP radiograph of the leg reveals a transverse band of sclerosis through the distal fibular metaphysis. The patient is a runner and reports pain over the fibula 20 minutes into his run. Which diagnosis is likely?
- Myositis ossificans
  - Shin splints
  - Compartment syndrome
  - Stress fracture**
- 
- 15.) Degenerative disc space narrowing leads to which of the following complications. (multiple)
- Lateral listhesis
  - Retrolisthesis
  - Disc herniation
  - Ligament hypertrophy
- 16.) Osteoarthritis describes reactive changes to stresses in which articulation. (multiple)
- Uncovertebral joint
  - Intervertebral disc joint
  - Sacroiliac joint
  - Apophyseal joint
- 17.) Which of the following sports injuries has a radiographic finding that must be differentiated from a malignancy?
- Stress fracture**
  - Plica
  - Avascular necrosis
  - Myositis ossificans
- 18.) The etiology of degenerative joint disease that most often presents in athletes.
- Ligament injury
  - Leg length inequality
  - Osteoporosis
  - Avascular necrosis
- 
- 19.) Select two sources of a disruption in the spinolaminar line between C1/2
- Short C1 arch
  - Rostrocaudal subluxation**
  - Transverse ligament tear
  - Ossification of PLL
- 20.) Which of the following contribute to degenerative joint disease? (multiple)
- Cartilage tear
  - Leg length inequality**
  - Epiphyseal injury
  - Rheumatoid arthritis

- 21.) Which of the following may be a complication of osteoarthritis?
- Osteosarcoma
  - Osteoma
  - Osteopetrosis
  - Osteonecrosis**
- 22.) A criterion for the radiographic diagnosis of spinal instability of C4/5?  
(multiple) *Seen on a lat. View*
- 3.5mm of translation (Horizontal)**
  - 11 degrees of body angulation**
  - Reversal of coupling
  - Narrowed Apophyseal joint
- 23.) Which of the following is a source of metastatic calcification?
- Hypercalcemia**
  - Athletic injury
  - Osteoarthritis
  - Infectious arthritis
- 24.) The most common congenital etiology of atlantoaxial instability is?
- Agensis transverse ligament,  $\rightarrow$  *Down's Syndrome*
  - Morquio's syndrome
  - Os odontoideum**
  - Grissel's syndrome
- 25.) Select findings seen with spondylotic myelopathy? (multiple)
- Clonus of the ankle - cord** *CORD UMNL*
  - Positive Babinski reflex - cord**
  - Loss of joint vibration - cord**
  - Loss of bladder control - cauda equina syndrome
- 26.) Herniation of the L4 disc may produce which sign? (L5 nerve root)
- Positive toe walk (S1)
  - Positive heel walk (L5)**
  - Loss of Achilles reflex (S1)
  - Weakened gluteus maximus 5<sub>1</sub>
- 27.) Select the complication associated with cervical syrinx:
- Glenohumeral instability**
  - Glenoid labral tear
  - Ankylosing spondylitis
  - Spondylolisthesis
- 28.) The method of radiographic analysis employing overlay techniques to determine mobility in the cervical spine is?
- McNab
  - Penning**
  - Nachemson
  - Mooney

- 29.) Select any possible source of spinal stenosis. (multiple)
- Ligamentous hypertrophy
  - Facet arthrosis
  - Rostrocaudal subluxation
  - Degenerative anterolisthesis
- 30.) Mechanical to electrical transduction triggers an osteoblastic response. This process is mediated by?
- Glucose shunt pathway
  - Lipase transition states
  - Stress generated biopotentials**
  - Mitochondrial hyperplasia
- 31.) Select a sign suggestive of radiculopathy: (multiple)
- Unilateral loss of Achille's reflex**
  - Bilateral biceps paresis**
  - Hyperreflexia - UMN
  - Spastic paresis - UMN
- 32.) The activation of muscle proprioceptors may stimulate which pathways? (multiple)
- Muscle afferents -**
  - Limbic
  - Cortex -**
  - Sympathetic ganglion
- 33.) Rostrocaudal subluxation arises secondary to:
- Spondylosis deformans**
  - Congenital defect
  - Facet arthrosis
  - Paget's disease
- 34.) Calcification observed radiographically within an abnormal aorta on a lateral lumbar x-ray measures 5.2cm. Select the follow up test.
- Arthrogram
  - Diagnostic ultrasound**
  - Bone scan
  - Thermogram
- 35.) The presence of atlantoaxial rotatory subluxation may be suspect from the radiographic series?
- 5 view cervical
  - 15 degree APOM
  - 7 view Davis series
  - Lateral flexion (bilateral)**
- 36.) The radiographic finding of cephalad subluxation of the glenohumeral joint raises the suspicion of:
- Chronic bicipital tendonitis
  - Acute Bicipital tendonitis
  - Rotator cuff tear
  - Glenohumeral joint arthrosis

- 37.) Claudication leg pain that is relieved by sitting warrants consideration of which diagnosis?
- a. Spinal stenosis
  - b. Cervical myelopathy
  - c. Postural subluxation
  - d. Sacroiliac arthritis

---

Midterm B

- 1.) Select the three sites of spinal stenosis: (multiple)
    - a. Lateral recess
    - b. Neuroforamen
    - c. Intervertebral disc
    - d. Central canal
  - 2.) Select the acceptable indications for full spine radiography: (multiple).
    - a. Clinical exam requires evaluation of multiple spinal sections
    - b. Severe postural distortion
    - c. Scoliosis evaluation
    - d. Patient education
  - 3.) Identify the diagnosis responsible for minimal pain, swelling, destruction and dislocation of the shoulder joint:
    - a. Syring
    - b. Syphilis
    - c. Diabetes
    - d. Tuberculosis
  - 4.) What is the mechanism of injury that produces a vertebral body compression fracture?
    - a. Flexion
    - b. Shear
    - c. Rotation
    - d. Extension
  - 5.) A patient sustained a thoracic spine injury with acute cord compression. What clinical finding was present?
    - a. Diaphragm paresis
    - b. Cauda equina syndrome
    - c. Reduced biceps reflex
    - d. Spastic paresis
  - 6.) Which of the following structures are likely to undergo injury in a cervical hyperflexion trauma? (multiple)
    - a. Pillar
    - b. Interspinous ligament
    - c. Anterior ligament
    - d. Ligamentum flavum
-

- 7.) Which of the following is likely to contribute to cervicogenic vertigo?
- Goiter
  - Apophyseal arthrosis**
  - Horner's syndrome
  - Trapezius trigger points
- 8.) Select the primary etiology for degenerative anterolisthesis?
- Uncovertebral arthrosis
  - Spondylolysis
  - Apophyseal arthrosis**
  - Herniation of nucleus pulposus
  -
- 9.) Select the etiology of an increased retropharyngeal space following spine injury.
- Nuchal ligament tear
  - Acute hematoma**
  - Clay-Shoveler's fracture
  - Anterior disc herniation
- 10.) The presence of the cauda equina syndrome is suggested by which sign?
- Chovstek's Sign
  - Babinski's sign
  - Hyper reflexia
  - Saddle distribution paresthesia**
- 11.) A lateral lumbar radiograph reveals no disc space thinning or apophyseal degeneration. There is ossification of the ALL across four segments. Consider which radiologic diagnosis?
- Spondylosis deformans
  - Osteoarthritis
  - Intervertebral osteochondrosis
  - DISH (diffuse idiopathic skeletal hyperostosis)**
- 12.) Select a "fingerprint" of a cervical flexion injury seen on a lateral radiograph:
- Anterior disc space widening **E<sub>2</sub>**
  - Pillar fracture
  - Segmental kyphosis** (perched forward, naked facet) **Grade III Str/Spr**
  - Retrolisthesis
- 13.) An AP radiograph of the foot reveals a horizontal band of sclerosis through the second metatarsal. The patient is a runner and reports pain in the location after training. Which diagnosis is likely?
- Morton's neuroma
  - Fatigue fracture** – aka Stress
  - Compartment syndrome
  - Insufficiency fracture
- 14.) Apophyseal joint arthrosis leads to which of the following complications.
- Segmental instability**
  - Retrolisthesis
  - Disc herniation
  - Ligament hypertrophy

- 15.) Which two levels of the cervical spine are most prone to injury?
- C2
  - C3
  - C5
  - C6
- 16.) The etiology of degenerative joint disease that most often presents in athletes.
- Ligament injury
  - Leg length inequality
  - Osteoporosis
  - Avascular necrosis
- 
- 17.) Select the most common source of disruption in the spionlaminal line between C1/C2.
- Short C1 arch
  - Rostrocaudal subluxation
  - Transverse ligament tear
  - Os odontoideum
- 18.) Which of the following disorders arise as a complication of steroid injections?
- Rheumatoid arthritis
  - Paget's disease
  - Epiphyseal injury
  - Neuroarthropathy**
- 19.) Which of the following may be a complication of osteoarthritis?
- Osteoma
  - Osteonecrosis**
  - Osteopetrosis
  - Osteoid Osteoma
- 
- 20.) A criterion for the radiographic diagnosis of spinal instability at C4/C5:  
(multiple)
- 3.5 mm of translation**
  - 11 degrees of body angulation**
  - Reversal of coupling
  - Narrowed apophyseal joint
- 21.) Select the fracture found in osteomalacia or Paget's disease?
- Impaction
  - Pseudofracture – blade of grass**
  - Avulsion
  - Green stick
- 22.) The most common etiology of atlantoaxial instability is:
- Agensis of transverse ligament
  - Rheumatoid arthritis**
  - Os odontoideum
  - Whiplash injury
- ADE

- 23.) ~~Posterior~~ Posterolateral herniation of the L5 disc may produce which sign?
- Neurogenic bladder
  - Positive heel walk
  - Loss of Achilles reflex
  - Weak Sartorius
- 24.) Select the finding typically associated with cervical Syrinx.
- Tarsal instability
  - Glenoid labral tear
  - Ankylosing spondylitis
  - Arnold-Chiari malformation**
- 25.) Which site in the cervical spine is most likely to be injured during spine trauma?
- Neural arch**
  - Posterior ligament
  - Transverse process
  - Spinous process

Matching Section - a.) benign or b.) malignant

- Enchondromatosis - a
- wide zone of transition - b
- vertical periostitis - b
- lymphoma - b
- osseous matrix - b
- fibrous dysplasia - a
- angulated endplate fracture - b
- rounded endplate fracture - a
- hemangioma - a
- enchondroma - a

- 36.) Your 55 year old male displays varus deformity of the knee. Which disorder is likely?

- RA
- Gout
- OA  $\in$
- Calcium pyrophosphate arthropathy

*alt osteophytes  
on medial side*

- 37.) Diffuse atherosclerotic disease in a 43 year old raises the question of which two etiologies?

- Hypothyroidism
- Diabetes
- Hyperthyroidism
- Hyperparathyroidism**

- 38.) Which of the following is a source of neuroforaminal encroachment?

- Segmental fixation
- Sclerosis
- Rostrocaudal subluxation**
- Segmental hypermobility

- 39.) Mechanical to electrical transduction regulates skeletal remodeling (Wolfe's Law). This process is mediated by:
- a. Quantum phase reversal
  - b. Lipase transition states
  - c. Electronic phase bypass
  - d. **Biopotential generation** *vibration?*
- 40.) Select a sign suggestive of myelopathy. (multiple)
- a. Reduced DTR
  - b. **Babiniski reflex**
  - c. **Hyper reflexia**
  - d. **Spastic paresis**
- 
- 41.) Activation of nociception following herniation may follow the release of which enzyme from the disc?
- a. Leukotriene
  - b. Substance P
  - c. **Phospholipase A2**
  - d. Phospholipase A1
- 42.) Rostrocaudal subluxation arises secondary to:
- a. **Discogenic spondylosis**
  - b. Congenital defect
  - c. Spondylolysis
  - d. Paget's disease
- 43.) The fracture that involves the base of the dens with extension into the C2 body is:
- a. Type I
  - b. Type II
  - c. **Type III**
  - d. Type IV
- 44.) The presence of a Grade II hyperflexion subluxation of the cervical spine may be suspect from which radiographic finding?
- a. Torticollis
  - b. Segmental rotation
  - c. **Interspinous gap - Grade II**
  - d. Bow tie sign - Grade III
- 45.) The type of odontoid fracture which is least stable is?
- a. Type I
  - b. **Type II**
  - c. Type III
  - d. Type IV
- 46.) The time interval to deliver a diversified P-A HVLA adjustment?
- a. 2.0 sec
  - b. 1.5 sec
  - c. **.5 sec**
  - d. .05 sec
-

47.) Select a radiographic sign of delayed fracture union.

- a. Endosteal callus
- b. Periosteal callus
- c. Decalcification of fragments
- d. Sclerosis of fragments

48.) What is the order of Fracture Healing?

- a. Hematoma formation
- b. Inflammatory response
- c. Granulation invasion
- d. Bone union
- e. Adult bone

Three phases of fracture healing are 1 - cellular/inflammatory, 2 - Metabolic/Reparative, 3 - Remodeling/Mechanical Phase

Midterm C:

1.) Select the etiology responsible for decreasing the volume of the intervertebral foramen: (multiple)

- a. Uncovertebral arthrosis
- b. Rostrocaudal subluxation
- c. Neurofibroma
- d. Apophyseal arthrosis

2.) Select the acceptable indications for full spine radiography: (multiple)

- a. Clinical exam requires evaluation of multiple spinal levels
- b. Severe postural distortion
- c. Scoliosis evaluation
- d. Patient education

3.) Identify the diagnosis responsible for minimal pain, swelling, destruction and dislocation of the hip joint:

- a. Syring
- b. Syphilis
- c. Diabetes
- d. Tuberculosis

4.) What is the mechanism of injury that produces an anterior longitudinal ligament tear?

- a. Flexion
- b. Shear
- c. Rotation
- d. Extension

5.) A patient sustained a cervical spine injury with acute cord compression. What clinical findings were present?

- a. Babinski sign
- b. Cauda equina syndrome
- c. Reduced biceps reflex
- d. Reduced triceps reflex

6.) Which of the following structures are likely to undergo injury in a hyperflexion trauma? (multiple)

- a. Pillar

b. **Interspinous ligament**

c. Anterior ligament

d. **Ligament flavum**

Matching Section

Fracture Eponym      Fracture Site

- 7.) Galleazzi – distal radial shaft fracture  
8.) Smith – distal radius displacement or reverse Colles' Fracture  
9.) Clay-Shoveler – spinous process  
10.) Jefferson – bursting neural arch  
11.) Pott's – distal fibula  
12.) Chance fracture – horizontal fracture through a single vertebrae (seatbelt)  
13.) Little Leaguer's elbow – avulsion of medial epicondyle  
~~14.) Colle's Fracture – radius 20-35 mm of joint and posterior angulation~~  
15.) Barton's Fracture – posterior rim of distal radius.  
16.) Bennett's – proximal head of 1<sup>st</sup> metacarpal  
17.) Jones – proximal head of 5<sup>th</sup> metatarsal  
18.) Monteggia – ulnar shaft of 4 in below olecranon  
19.) Hangman's/Hangee – C2/axix fracture

Matching

Roentgen Sign      Roentgen Diagnosis

- 20.) maxillary soft tissue mass – acute sinusitis  
21.) tilted dens – type II fracture  
22.) facet perched - strain  
23.) anterior meniscus – TMJ derangement  
24.) The activation of muscle proprioceptors may stimulate which pathways?  
(multiple)  
a. **muscle efferent**  
b. limbic  
c. **cortex**  
d. sympathetic ganglion  
25.) Rostrocaudal subluxation arises secondary to:  
a. **Spondylosis deformans/Discogenic spondylosis**  
b. Congenital defect  
c. Facet arthrosis  
d. Paget's disease  
26.) Calcification observed radiographically within an abnormal aorta on a lateral lumbar x-ray measures 5.2 cm. Select the follow up test:  
a. Arthrogram  
b. **Diagnostic ultrasound**  
c. Bone scan  
d. thermogram  
27.) The presence of atlantoaxial rotatory subluxation may be suspect from which radiographic series?  
a. 5 view

- b. 15 degree APOM  
c. 7 view  
d. **Lateral flexion (bilateral)**
- 28.) The radiographic finding of cephalad subluxation of the glenohumeral joint raises suspicion of:  
a. Chronic Bicipital tendonitis  
b. Acute Bicipital tendonitis  
c. **Rotator cuff tear**  
d. Glenohumeral joint osteoarthritis
- 29.) Claudication pain in the legs that is relieved by sitting warrants consideration of which diagnosis?  
a. Spinal stenosis  
b. Cervical myelopathy  
c. **Postural subluxation**  
d. Sacroiliac arthritis
- 30.) Select findings seen with spondylotic myelopathy? (multiple)  
a. **Clonus of the ankle**  
b. **Positive Babinski reflex**  
c. **Loss of joint vibration**  
d. Loss of bladder control – cauda equina
- 31.) Herniation of the L4 disc may produce which sign? (L5 nerve root)  
a. Positive toe walk – S1  
b. **Positive heel walk – L5**  
c. Loss of Achilles reflex – S1  
d. Weakened gluteus maximus – S1
- 32.) Select the complication associated with a cervical syrinx:  
a. **Glenohumeral instability**  
b. Glenoid labral tear  
c. AS  
d. Spondylolisthesis
- 33.) The method of radiographic analysis employing overlay techniques to determine mobility in the cervical spine is?  
a. McNab  
b. **Penning**  
c. Nachemson  
d. Mooney
- 34.) Select any possible source of spinal stenosis: (multiple)  
a. **Ligamentous hypertrophy**  
b. **Facet arthrosis**  
c. **Rostrocaudal subluxation**  
d. **Degenerative anterolisthesis**
- 35.) Select a sign suggestive of radiculopathy: (multiple)  
a. **Unilateral loss of Achilles' reflex**  
b. **Bilateral biceps paresis**  
c. **Hyperreflexia**
- Ag 1002 7

- 36.) d. Spastic paresis  
The etiology of DJD that most often presents in athletes:
- a. Ligament injury
  - b. Leg length inequality
  - c. Osteoporosis
  - d. Avascular necrosis
- 37.) Select two sources of a disruption in the spinolaminar line between C1/C2:
- a. **Short C1 arch (most common)**
  - b. **Rostrocaudal subluxation**
  - c. Transverse ligament tear
  - d. Ossification of PLL
- 38.) Which of the following contribute to degenerative joint disease: (multiple)
- a. Cartilage tear
  - b. **Leg length inequality**
  - c. **Epiphyseal injury**
  - d. RA - infectious
- 39.) Which of the following may be a complication of osteoarthritis?
- a. Osteosarcoma
  - b. Osteoma
  - c. Osteopetrosis
  - d. **Osteonecrosis**
- 40.) A criterion for the radiographic diagnosis of spinal instability of C4/5:  
(multiple)
- a. **3.5mm of translation**
  - b. **11 degrees of angulation**
  - c. Reversal of coupling
  - d. Narrowed apophyseal joint
- 41.) Which of the following is a source of metastatic calcification?
- a. **Hypercalcemia**
  - b. Athletic injury
  - c. Osteoarthritis
  - d. Infectious arthritis
- 42.) The most common congenital etiology of atlantoaxial instability is:
- a. **Agenetic transverse ligament** *Down Syndrome*
  - b. Morquio's syndrome
  - c. ~~Os odontoidum~~
  - d. Grissel's Syndrome
- 43.) The SSEP exam evaluates which property of axons?
- a. Axoplasmic velocity
  - b. **Latency period**
  - c. Adventitial period
  - d. Reperfusion period
- 44.) The fingerprints of a cervical extension injury seen on a lateral radiograph:  
(multiple)
- a. **Anterior disc space widening**
  - b. **Pillar fracture**

WHAT  
IS IT?

- 45.) The AP radiograph of the leg reveals a transverse band of sclerosis through the distal fibular metaphysis. The patient is a runner and reports pain over the fibula 20 minutes into his run. Which diagnosis is likely?
- a. Myositis ossificans
  - b. Shin splints
  - c. Compartment syndrome
  - d. Stress fracture
- 46.) Degenerative disc space narrowing leads to which of the following complications: (multiple)
- a. Lateral listhesis - selected
  - b. Retrolisthesis - selected
  - c. Disc herniation - selected
  - d. Ligament hypertrophy - selected
- 47.) Osteoarthritis describes reactive changes to stresses in which articulation: (multiple)
- a. Uncovertebral joint
  - b. Intervertebral disc joint
  - c. Sacroiliac joint
  - d. Apophyseal joint
- 48.) Which of the following is likely to contribute to chronic joint instability?
- a. Tendonitis
  - b. Proprioceptive dysfunction - selected
  - c. Hypertonic musculature
  - d. Capsular ischemia
- 49.) Select the primary etiology for degenerative anterolisthesis?
- a. Uncovertebral arthrosis
  - b. Spondylolysis
  - c. Apophyseal arthrosis
  - d. Herniation of nucleus pulposus
- 50.) Non-union of a fractured carpal is likely to occur at which site?
- a. Lunate
  - b. Hamate
  - c. Scaphoid - loses the blood supply
  - d. Pisiform
- 51.) Select an etiology of an increased retropharyngeal space.
- a. Nuchal ligament tear
  - b. Acute hematoma
  - c. Clay-shoveler's fracture
  - d. Anterior disc herniation
- 52.) The presence of the cauda equina syndrome is suggested by which sign?
- a. Chovstek's sign
  - b. Babinski's sign
  - c. Hyper reflexia

Synovial

chronic joint instability?

Synovial

- d) Saddle distribution paresthesia
- 53.) A lateral lumbar radiograph reveals no disc space thinning or apophyseal degeneration. There is ossification of the ALL across four segments. Consider which radiologic diagnosis?
- Spondylosis deformans
  - OA
  - Intervertebral osteochondrosis
  - DISH**
- 54.) A Bennett's fracture occurs in which location?
- Radius
  - Ulna
  - Talus
  - Metacarpal**
- 55.) The radiographic definition of the abdominal aortic aneurysm is suggested by which measurement?
- 0.8 cm
  - 1.8 cm
  - 2.8 cm
  - 3.8 cm**
- 
- 56.) A thick sclerotic, irregular, serpentine collection of osseous density in the medullary canal warrants consideration of:
- Bone island
  - Bone infarction**
  - Pulmonary mets
  - Osteomalacia
- 57.) Select the benign lesion found most often in the epiphysis:
- Osteoma
  - Chondroblastoma**
  - Osteoid Osteoma
  - Fibrous dysplasia
- 58.) A lytic lesion in the spine of a 73 year old female is probably metastatic from which site? Mets Breast/Lung
- Thyroid
  - Osteosarcoma
  - Kidney
  - Lung**
- 
- 59.) The most common malignancy of the skeleton:
- Metastatic carcinoma**
  - Osteosarcoma – kids knee
  - Mesothelioma – asbestos
  - Multiple myeloma – most common primary
- 60.) The diagnostic evaluation that is employed to detect the presence of multiple myeloma is:
- ESR
  - CT

- c. Bone scan
- d. Immunoelectrophoresis - IgG

Midterm D.

- 1.) 55 year-old male presents with chronic LBP. On review of systems he states that he is having difficulty initiating a urinary stream. The problem began a few days prior to evaluation. The vital signs were BP 150/96, pulse 92, respirations 20 and temp 99 degrees. His physical revealed a palpable mass extending into the suprapubic region. Ortho exam was positive on Kemps bilaterally. Neuro exam yielded bilaterally diminished S1 reflexes. Radiographs of the lumbar spine and pelvis demonstrated arthrosis and spondylosis. The bladder was displaced from midline. What additional imaging exam does this patient require?
- a. IVP
  - b. Pelvic MRI
  - c. Chest series
  - d. Head MRI
- 2.) What is your diagnostic suspicion of the patient described above?
- a. Prostate carcinoma
  - b. Rectal carcinoma
  - c. Urolithiasis
  - d. UTI
- 3.) Persistence of a hiatal hernia with reflux may give rise to which premalignant complications?
- a. Esophageal varices
  - b. Achalasia
  - c. Candidiasis
  - d. Barret's Esophagus
- 4.) A radiolucent mass associated with calcifications resembling teeth noted in the pelvis. What morphological pattern is demonstrated by these findings?
- a. Solid mass
  - b. Conduit
  - c. Cyst
  - d. Concentration
- 5.) What is the clinical significance of this finding?
- a. Raises risk of obstruction
  - b. None
  - c. Premalignant
  - d. Predisposes to UTI
- 6.) Radiographic evidence of osteolytic destruction is found crossing several adjacent tarsal bones. Soft tissue swelling is prominent. Subcutaneous emphysema is noted and damage to the plantar ligament. What additional clinical feature is likely to be present in this patient?
- a. Shoulder dislocation
  - b. Argyll-Robertson pupil
  - c. Cauda equina syndrome



- 
- a. Hyperparathyroidism  
b. Os-odontoidum - select  
c. Addison's disease  
d. Paget's disease
- 16.) A soft tissue mass with obtuse borders along the pleura on a chest or rib film suggests:  
a. Silhouette sign  
b. Adenopathy  
c. **Extra pleural sign**  
d. Atelectasis
- 17.) The most likely differential consideration for the mass referred to in the previous question: (extra pleural sign – indicates either hematoma after fracture or metastasis)  
a. Rib metastasis  
b. Pulmonary edema  
c. Pleural effusion  
d. Bronchogenic carcinoma
- 
- 18.) Bilateral pulmonary adenopathy in an asymptomatic black female is suggestive of:  
a. Pneumonia  
b. Asbestosis  
c. Sarcoidosis - selected  
d. Congestive failure
- 19.) Pulmonary bullae may provoke which complication?  
a. Aneurysm  
b. Adenopathy  
c. Emphysema  
d. **Pneumothorax**
- 20.) A small heart shadow, hyperlucent lungs and flat diaphragm suggests:  
a. Congestive heart failure  
b. **Emphysema**  
c. Hypertension  
d. Pneumonia
- 21.) Which technical factors increases the heart size on chest radiography?  
(multiple)  
a. **AP projection**  
b. Inspiration  
c. **Expiration**  
d. Lateral decubitus
- 
- 22.) Chronic hypertension will likely impact which cardiac chamber initially?  
a. Right ventricle  
b. **Left ventricle**  
c. Left atrium  
d. Right atrium
- 23.) Select three sites where renal stone impaction are likely:  
a. Ureteral pelvic junction - selected

- b. Mid-ureter
  - c. Brim of pelvis - selected
  - d. Ureterovesical junction - selected
- 24.) Select two sites where Paget's presents in the lytic phase:
- a. Vertebral column
  - b. Long bones
  - c. Skull
  - d. Pelvis

↓ This was pretty much the mid-term Fall 2007!

### Hand Written Notes of Possible Questions

- 1.) What appears white on a T2 MRI image?
  - a. CSF and Disc
- 2.) Pain with gapping between spinous processes of C5/C6 are caused by what type of injury?
  - a. Flexion

---

- 3.) 95% of all glenohumeral dislocations are in which direction?
  - a. Anterior - the shoulder joint also accounts for 50% of all body fractures, Hill-Sachs deformity is closely associated with ant dislocation of the humerus
- 4.) Which of the following sports injuries has radiographic finding that must be differentiated from malignancy?
  - a. Myositis ossificans or stress fracture - multiple small injuries or repetitive trauma is commonly required for these
- 5.) What is the best tool for viewing of the spinal cord?
  - a. MRI
- 6.) Which can be found in the apex of the lung?
  - a. pancoast tumor
- 7.) What symptom is associated with the above?
  - a. Horner's syndrome - anhydriasis, ptosis, mydriasis
- 8.) 2 signs of instability
  - a. 3.5mm translation or 11 degrees angulation
- 9.) Tracheal deviation after MVA most likely?
  - a. Hematoma

---

- 10.) Select complication of fracture resulting in osteolysis and periosteal reaction at fracture site?
  - a. Osteomyelitis
- 11.) Radiographic sign of non-union?
  - a. Sclerosis of fx margin
- 12.) Radiographic finding of synovial chondrometaplasia? - pg 1006-10
  - a. Multiple joint mice - in this condition there are multiple cartilaginous fragments within the joint space that over time ossify.

pseudo-sarcoma appearance of post-traumatic myositis ossificans (MO). How to tell the difference? MO has lucent zone between (clearance)

13.) Fracture through physis and metaphysis

a. Type II Salter Harris

### Salter Harris Classifications

a.) Type I - Physis

b.) Type II - Physis & Metaphysis

c.) Type III - Physis & Epiphysis

d.) Type IV - Combo of all three

e.) Type V - Compression

14.) Facet OA and Uncovertebral arthrosis can lead to?

a. Degenerative instability

15.) Most common fracture of C1?

a. Post arch - 50% of C1 fractures

16.) Most frequent location of pathologic hip fracture?

a. subcapital

17.) Radiographic sign of non union?

a. Sclerosis of fracture margins

18.) What force causes a Jefferson's fracture?

a. Axial compression

19.) Three fractures by hyperextension?

a. Hangmans, odontoid, and ext. tear drop - U

20.) Most common complication of femur neck fracture?

a. Osteonecrosis

21.) Most common tarsal and carpal fractures?

a. Calcaneal and Scaphoid

22.) 2 areas affected by Uncovertebral arthrosis?

a. FVT and vertebral artery

23.) Fracture that breaks through the skin

a. Compound

24.) Fracture that doesn't break through the skin.

a. Closed

25.) Type of break that indicates pathology?

a. Transverse - fracture runs at a right angle to the long axis of the bone and is commonly seen in pathologic process "banana transverse pathologic fracture"

26.) What fracture causes horizontal fracture through the body, arch and spinous?

a. Chance fracture/seatbelt - horizontal splitting of the spinous process and pedicle continuing through the posterior body into the superior endplate

27.) Pt with bilateral erythema, pain and edema in hands, sclerosis, symmetrical joints, osteolysis of proximal joint?

a. Choices were OA, RA, EOA

ON A-P x-ray "double spinous" sign

- 28.) Clay Shovler's - avulsive fracture of the spinous process from extreme flexion and most commonly in the lower cervical and upper T-spine which is pulled off from the musculotendon attachment.
- 29.) 5 degree tilt of odontoid on APOM? Type II
- 30.) The most common fracture of the elbow in adults?  
a. Radial head (50% of all elbow fractures)
- 31.) Sign of Jefferson fracture: - bursting fracture of the atlas of the ring of the atlas. It is a compression fracture due to the load from the occipital condyles applying the force on the lateral masses of C1.  
a. Separation of the lateral masses
- 32.) What sign is present in elbow injury?  
a. Positive fat pad sign - confuse post?
- 33.) Which one is diastatic fracture?  
a. Pubic symphysis - this is a frank separation of a syndesmosis bone. m/e is the pubic symphysis
- 34.) Difference between soft tissue masses and myositis ossificans? no  
a. Myositis ossificans is a condition where cartilage fragments ossify with a single joint space from trauma
- 35.) Case study about man with cervical pain, B/L leg weakness, hyper reflexia of S1 DTR and quad spasms?
- 36.) What are the findings associated with Cauda equina syndrome?  
a. Lower extremity paresis, saddle paraesthesia, incontinence
- 37.) With a tumor in the apex of the lung what symptoms would you expect to be associated?  
a. Aka Horner's - miosis, anhidrosis, ptosis
- 38.) What could cause a flow void on a T2 weight image following a MVA w/ vertigo?  
a. Dissection, aneurysm or atherosclerosis
- 39.) Extradural mass - degenerative stenosis, ependyoma, Syrinx
- 40.) 3 radiographic signs of compression fracture:  
a. Step defect, wedge deformity, linear zone of condensation, endplate displacement, paraspinal swelling, psoas obliterations, abnormal small bowel gas (Table 9-10, pg. 838)

what would cause lack of flow void on axial MRI

### Fractures

- 1.) Most common fracture of the facial bones - tripod fracture (blow to the face over the malar)
- 2.) Jefferson Fracture - Bursting forth of C1 from compressive load that fractures the lateral masses from the overload from the occipital condyles
- 3.) Posterior Arch Fracture of C1 - most common at 50% of atlas fracture caused by increase force from hyperextension
- 4.) Anterior Arch Fracture of C1 - avulsion fracture caused by hyperextension
- 5.) Transverse Ligament Rupture - least common you will have a Jefferson's fracture first because the ligament is so strong. Conditions for exception are: RA, AS, Reiter's and Down Syndrome

see Yochum & Rowe pg 936 Table 9-20. can't remember the question might have been Pott's fracture

What is double fracture of leg? bi-malleolar

Mechanism of spinal stenosis in DISH? PLL

- 6.) Hangerman's Fracture – most common fracture of the c-spine is of C2 at the neural arch. This is a bilateral disruption of the pedicles of the axis caused by deceleration hyperextension situation and in the case of judicial hangings.
- 7.) Teardrop fracture – avulsion fracture of the triangular shaped fragment of the axis body also a hyperextension injury
- 8.) Odontoid Process Fracture –
  - a. Type I – avulsion of the tip of the odontoid as result of an apical or alar ligament stress
  - b. Type II – fracture at the junction of the process and the body of the C2 vertebrae – tends to form a non-union, tx is halo head gear with surgery last resort – **most common**
  - c. Type III – fracture is deep within the vertebral body – uncommon and usually heals with a reunion of the body
- 9.) Compression Fracture –
  - a. Wedged fracture – hyperflexion induced stable fracture and most common at C5-7 - *Decrease of vert. vertebral body height*
  - b. Burst fracture – compressive force that shoves the nucleus pulposus through the endplate of the vertebrae causing a vertical fracture of the body
  - c. Teardrop fracture – a triangular shaped bone that has been pulled from the anterior inferior corner of the vertebral body. Commonly a hyperextension injury and avulsive process
  - d. Radiographic Findings - Step defect, wedge deformity, linear zone of condensation, endplate displacement, paraspinal swelling, psoas obliterations, abnormal small bowel gas (Table 9-10, pg. 838)
- 10.) Malgaigne's Fracture – double injury to one hemipelvis which is an ipsilateral double vertical fracture
- 11.) Bucket-Handle Fracture – a fracture through the superior pubic ramus and ischial pubic junction and a dislocation of the SI joint on the same side.
- 12.) Most common fracture of the wrist is at the distal radius
  - a. Colles' Fracture – distal radius fracture and posterior angulation, quadratus fat plane, usually a transverse and comminuted fracture – this is from falling on an out stretched hand (**FOOSH**)
- 13.) Smith's Fracture (Reversed Colles' Fracture) – fracture of distal radius with anterior angulation – fall and the wrist is forced into hyperflexion.
- 14.) Barton's (Rim) Fracture – fracture of the distal radius rim where the carpals migrate posterior
- 15.) Scaphoid Fracture – these fractures usually occur between 15–40 y.o. There are three divisions of the Scaphoid distal pole, waist and proximal pole.
  - a. Waist – most common fracture **70%** and is a transverse fracture
  - b. Most common complication is necrosis, non-union, carpal DJD and carpal instability
- 16.)

Another Great Study Guide

- 1.) Cause of degenerative Spondylolisthesis?

*unate  
subwa*

- a. Degeneration of facets – allows the body to slip forward
  - b. Over 40 yoa-female, arthritis at L4/5, facet joint arthrosis
- 
- 2.) Which dens fracture has a 5 degree tilt?
- a. Type II
    - i. 3 Dens fractures
      - 1. Tip (least problematic)
      - 2. End (m/c)
      - 3. Intro-body fracture: dens & part of vertebrae is broken off
- 3.) How do you know a fracture is non-union?
- a. Fracture margin rounding, sclerotic fracture margins, pseudoarthrosis, lack of callus
- 4.) Know synoviochondrometaplasia (joint mice).
- a. Degenerative arthritis
  - b. Brief definition – benign arthropathy characterized by formation of intraarticular loose bodies with variable symptoms
  - c. Key clinical features:
    - i. 30-50 yoa male 3:1
    - ii. Often from a trauma and m/c site is knee (70%), hip (20%), elbow, ankle, shoulder, wrist,
  - d. radiographic features
    - i. maybe normal if loose bodies are not calcified or ossified
    - ii. loose bodies are round to ovoid, smooth faceted, laminated, or stippled, may have internal trabeculae
    - iii. occasional extrinsic bone erosion (apple core deformity)
- 
- 5.) Most common tarsal and carpal fracture
- a. Scaphoid fx – most common between 15-40
    - i. Rare in children
    - ii. m/c for occult fx
    - iii. mechanism – same amt of hyperextension and radial flexion
      - 1. FOOSH
      - 2. Herbert's pin needed if doesn't heal
      - 3. avascular necrosis can occur – retrograde susception
  - b. Calcaneus – most common ankle bone to fracture
    - i. Boehler's angle is crucial for diagnosis
    - ii. Less than 28 degrees – fracture likely
    - iii. Talus is 2<sup>nd</sup> m/c
- 
- 6.) Know linear zone of condensation
- a. Linear white band of condensation (zone of impaction)
  - b. Occasional sign – radiopacified band below fractured superior endplate, site of bone, impaction and later callus formation, denote recent fracture
- 7.) signs of instability
- a. c-spine – greater than 3.5mm of anterior slippage or 11 degrees of angulation
  - b. L-spine – meyerding grading scale
- 
- 8.) With patellar dislocation look \_\_\_\_\_ on x-ray
- a. Tangential knee projection (skyline, sunrise)

- i. Lateral patellar displacement
  1. line drawn tangential to highest margin of femurs
  2. line drawn perpendicular to this at medial lip of the intercondylar sulcus
    - a. should be 1mm or less

9.) Most common missed fracture?

- a. Pillar fracture

10.) Which of these is an intracapsular fracture?

- a. Hip—femoral head and neck proximal to trochanters

11.) Most common proximal femur fracture?

- a. Subcapital – junction of head and neck

12.) Malgaigne fracture involves?

- a. Double injury to one hemi-pelvis

13.) Which way does the shoulder go with an A-C tear?

- a. Shoulder will go inferior
- b. Clavicle will go superior

14.) Know Erosive OA

- a. A type of degenerative – DJD
  - i. Erosive OA – inflammatory, 4-5 decade

15.) Chance (seatbelt) fracture

- a. Chance – horizontal fracture thru vertebra
  - i. Sudden deceleration with lap-only seatbelt
  - ii. Usually L1/2

16.) What part of the clavicle is most commonly fracture?

- a. Middle is most common
- b. Medial is least common

17.) Bar Room Fracture

- a. Bar room – 4<sup>th</sup> and 5<sup>th</sup> metacarpal
- b. Boxer – 2<sup>nd</sup> and 3<sup>rd</sup> metacarpal
- c. Bennet's – 1<sup>st</sup> thumb metacarpal

18.) Know difference in torus and greenstick fracture:

- a. Both are incomplete
- b. Torus – buckling fracture, compressive bulges, cortex outward
- c. Greenstick – bent, bond fracture on convex side, concave intact

19.) Myositis ossificans presents with?

- a. Heterotrophic bone formation at site of trauma
- b. Usually at thigh or anterior arm
- c. Plain film shows confluent ossification in muscle tissue

20.) Patient is 40, female, L4?

- a. Spondylolisthesis

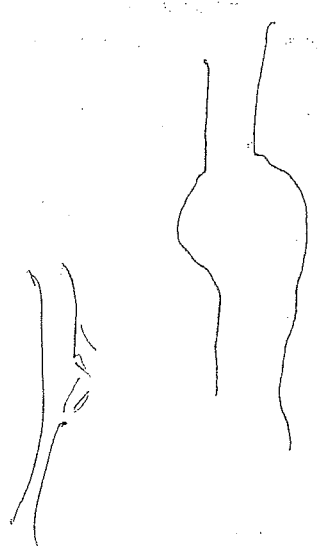
21.) Know L5-S1 herniation. How will patient present – S/S

- a. Positive toe walk, Achilles

22.) Three locations of FOOSH fracture:

- a. Scaphoid, radial fracture of elbow, and greater tuberosity

23.) Most common site of OA?



- 24.) a. Spine, knee, hip  
b. Know tear-drop fracture  
c. Patient won't walk in due to quadriplegia  
d. Triangular fracture of anterior  
e. Unstable  
f. Ligaments are disrupted
- 25.) a. Common cause of epidural cord compression?  
b. HNP, spinal canal stenosis
- 26.) a. Know double spinous sign?  
b. Clay-shoveler's fracture – abrupt flexion
- 27.) a. Fracture presents with skin rupture?  
b. Open or compound
- 28.) a. Rectus femoris avulsion fracture:  
b. AHS
- 29.) a. Hamstring avulsion fracture:  
b. Ischial tube
- 30.) a. Know Maisonneuve's fracture:  
b. Inversion with external rotation of the foot  
c. Fractures proximal fibular shaft  
d. Commonly missed due to extreme ankle pain
- 31.) a. T2 show – white  
b. CSF and disc
- 32.) a. Pick findings associated with cauda equina syndrome:  
b. LE paresis, saddle paresthesia, incontinence
- 33.) a. Pain with gapping between sp of C5/6 – double spinous  
b. Clay shovelers
- 34.) a. Which sports injuries has a radiographic finding that must be differentiated from malignancy?  
b. Avascular necrosis, stress fracture
- 35.) a. Best image for cord?  
b. MRI – T1 – fat and myelin
- 36.) a. Which is found at the apex of the lung?  
b. Pancoast tumor/sulcus tumor
- 37.) a. What symptoms are associated with the above question?  
b. Horner's – anhidrosis, miosis, ptosis
- 38.) a. Tracheal deviation after an MVA most likely?  
b. Hematoma, abscess
- 39.) a. 65 year old woman with stumbling gait, b/l loss of sensory to feet, osseous bridging of calcaneus and talus, taping distal toes?  
b. Charcot's joints
- 40.) a. What are associated symptoms of charcots?  
b. Hypertensive retinopathy
- 41.) a. Complication of fracture resulting in osteolysis and periosteal reaction at fracture site?  
b. Osteomyelitis
- 42.) a. Flow void on T2 after MVA with vertigo?

- a. Dissection
- 43.) Common cause of epidural masses?

---
- a. Degenerative stenosis, HNP
- 44.) Three signs of compression fracture:
  - a. Line of condensation, step defect, wedge deformity
- 45.) Facet OA and Uncovertebral arthrosis can lead to?
  - a. Degenerative instability
- 46.) Most common fracture of C1?
  - a. Posterior
- 47.) Mechanism of hangman's fracture:
  - a. Hyperextension
- 48.) Force that causes Jefferson's fracture?
  - a. Axial compression
- 49.) Three fractures caused by hyperextension?
  - a. Hangmans, posterior arch/odontoid, teardrop
- 50.) 5 degree tilt of odontoid on APOM:
  - a. Type II
- 51.) Two areas affected by uncovertebral arthrosis?
  - a. IVF and vertebral artery
- 52.) Type of break indicating pathology?
  - a. Transverse
- 53.) Most common avulsion in malignancy?

---
- a. Lesser trochanter on femur
- 54.) Some questions with DIP and PIP:
  - a. DIP - OA, PIP - OA & RA, MCP - RA